

# Case Report

## Osteogenic Sarcoma of the Maxilla: Case Report

Cintia Milani Contar, DDS, MS;<sup>1</sup> Acir Dirschnabel, DDS, MS;<sup>1</sup> Magna Thiele, DDS, MS;<sup>1</sup> Carla Maffei, SLP, MS;<sup>1</sup> Wilson Dênis Martins, DDS, PhD;<sup>2</sup> Marina de Oliveira Ribas, DDS, PhD<sup>2</sup>

1 Postgraduate Student, Department of Stomatology, School of Dentistry, Pontifícia Universidade Católica do Paraná, Curitiba, Brazil

2 Professor of Oral Surgery, Pontifícia Universidade Católica do Paraná, Curitiba, Brazil.

Institution in which the work was developed: Pontifícia Universidade Católica do Paraná

### Abstract

Osteosarcoma (OS) is one of the most common primary malignant bone neoplasms, which predominantly occurs in the long bones and rarely in the maxillofacial area. We present a rare case of maxillary OS early diagnosed in a 17-year-old girl through clinical, radiological and histological examination. The treatment involved surgical resection of the tumor followed by radiation therapy and chemotherapy. The patient was much younger than the average age of presentation of a jaw tumor, which typically presents in the third to fourth decades of life. Although there is a consensus in the literature that OS of the jaws is less aggressive and less prone to metastasis than OS of the long bones, that was not true in this case, where in spite of early diagnosis and treatment the patient died due to brain metastasis.

**Keywords:** Osteosarcoma. Maxillary Neoplasms. Neoplasm Metastasis. Sarcoma.

### Introduction

Osteosarcoma (OS) is a malignant mesenchymal tumor whose cancerous cells produce osteoid or immature bone.<sup>1-2</sup> It is one of the most common primary malignant bone neoplasms, second only to multiple myeloma.<sup>3-4</sup> Most osteosarcomas (from 55% to 65%) are located in the long bones, and only 5% to 6% arise occur in the jaws.<sup>4</sup> The body of the mandible and the alveolar ridge of the maxilla are the most frequently affected sites.<sup>1,3-5</sup>

The average age at onset of OS in the maxillofacial region is about one or two decades later than their long bone counterparts, which have a peak incidence between the ages of 10 and 14 years.<sup>2,6-7</sup> In addition, OS of the maxillofacial region is associated with a lower metastatic rate than is long bone osteosarcoma and the prognosis is significantly better.<sup>1-2</sup>

Herein we present a rare case of maxillary OS in a 17-year-old-Brazilian girl, who died of cerebral metastasis in spite of early diagnosis and treatment.

### Case Report

A 17-year-old girl presented to the Stomatology Service of Pontifícia Universidade Católica do Paraná, with a complaint of swelling of the left cheek with onset two weeks earlier. Her past medical and family history was unremarkable. Extraoral examination revealed a swelling in

---

#### Correspondence

Cintia Milani Contar

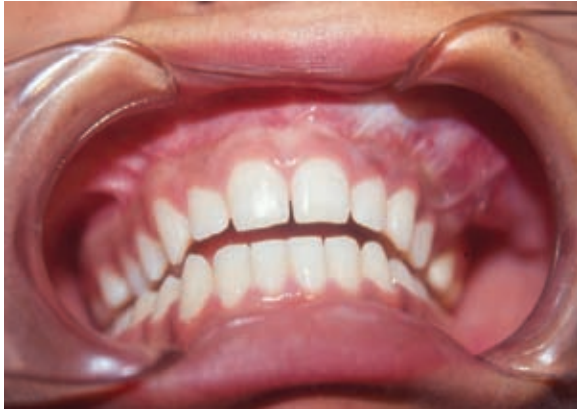Av. Visconde de Guarapuava, 4177/1301

Curitiba, Brazil,

Phone: 55 41 88364204

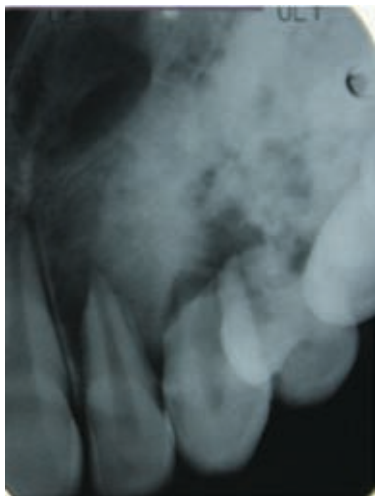Email: cintiacontar@hotmail.com.

the left maxillary region, hard in consistency and painless upon palpation, which caused deletion of nasolabial fold and rising of the alar nasi. Intraoral examination showed a maxillary alveolus swelling extending from the left lateral incisor to the left second molar (Figure 1). Teeth were not loose.

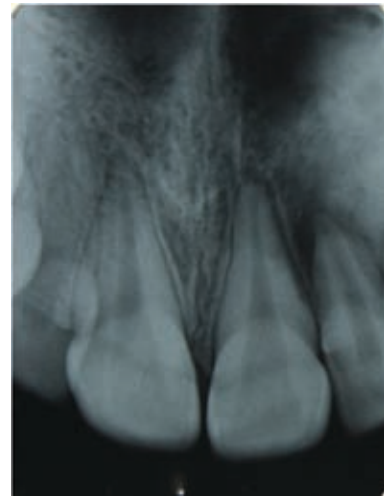


**Figure 1** - Intraoral view: left maxillary buccal mucosa swelling

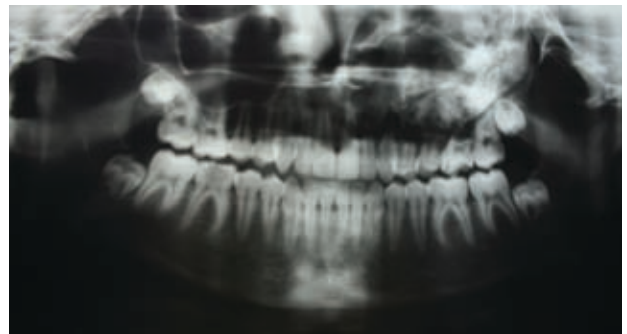
A periapical radiography showed radicular resorption and a diffuse radiopaque lesion on the 23 and 24 periapex (Figure 2). In addition, a widening of the periodontal ligament space of the central and lateral incisor was observed (Figure 3). A panoramic radiography showed a radiopaque lesion affecting the left maxilla body with maxillary sinus invasion. However, the posterior maxillary wall was preserved (Figure 4).



**Figure 2** - Periapical radiograph showing extensive root resorption of canine and pre-molar

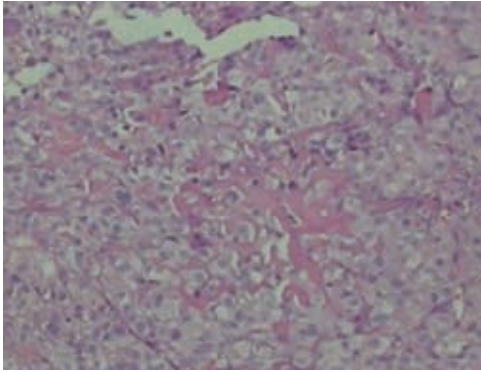


**Figure 3** - Periapical radiograph: widening of periodontal ligament space of left lateral and central incisor

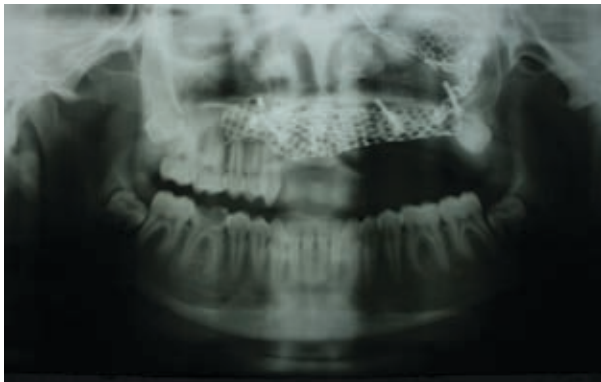


**Figure 4** - Panoramic radiograph showing the left hemimaxilla and maxillary sinus involvement. Notice the preservation of the posterior maxillary wall

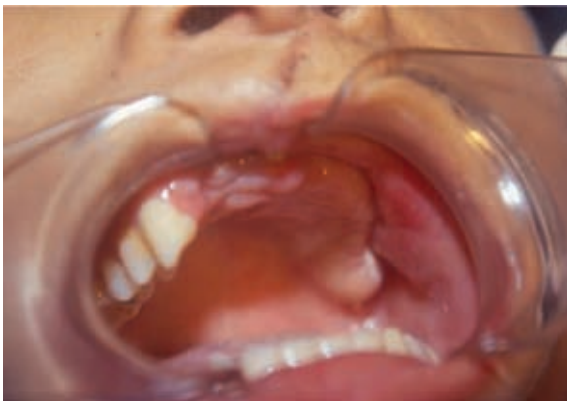An incisional biopsy was carried out under local anesthesia and the histological examination revealed basophilic calcification areas surrounded by sheets of neoplastic cells and some areas of osteoid material (Figure 5). Microscopic diagnosis was osteoblastic osteosarcoma. The patient was referred to the Oncology Hospital, where she was treated with surgical resection of the hemimaxilla with preservation of the posterior maxillary wall, which was margin free. Reconstruction with titanium mesh and screws was carried out at the same time (Figures 6 and 7). The patient was also submitted to radiation therapy and chemotherapy. One year after the surgical procedure, she started experiencing dizziness and fainting; at that time, a diagnosis of cerebral metastasis was done. The patient died six months later.



**Figure 5** - Histological aspect showing basophilic calcification areas surrounded by sheets of neoplastic cells and some areas of osteoid material



**Figure 6** - Panoramic radiograph showing the reconstruction of the osseous defect with titanium mesh and screws



**Figure 7** - Intraoral view after surgical resection

## Discussion

Osteosarcoma is one of the most frequent malignant bone tumors. However, sarcomas in the oral and maxillofacial region are very rare.<sup>8-9</sup> The pathogenesis of the tumor remains unknown but various predisposing factors such as radiotherapy, viral agents, genetic factors, and preexisting conditions (bone cysts, fibrous dysplasia, osteochondroma) are associated with the tumor.<sup>4</sup> In this case there were no predisposing factors. The patient's medical and familial history was unremarkable.

The highest occurrence of osteosarcoma in the maxillofacial region occurs in the third to fourth decade of life, ten to twenty years later than the peak incidence of osteosarcomas of other regions.<sup>2,6</sup> This patient was only 17 years old, much younger than the average age for presentation of a tumor in the jaws; this may have contributed to the unusual progression of the disease.

There is no consensus in the literature regarding gender distribution. Some authors report no gender predilection,<sup>2,8</sup> while others suggest there is a greater number of males with OS.<sup>3-5,7,9-12</sup>

The most common initial signs and symptoms associated with osteosarcoma of the jaws are swelling of the involved region, pain, gingival bleeding, mobility and displacement of the associated teeth and paresthesia/anesthesia.<sup>2-4</sup> In this patient the only sign was swelling of the involved area. What called attention to the area was the rapid progression of the swelling; according to the patient, the onset was just two weeks earlier.

Radiographically the tumor can be radiopaque, radiolucent or mixed, depending on the degree of ossification and mineralization.<sup>3,7</sup> The peripheral border is usually ill-defined and indistinct.<sup>13</sup> Osteophytic bone production on the surface of the lesion causes a sunburst or sun-ray appearance and is observed in approximately 30% of jaw osteosarcomas.<sup>2-3</sup> The widening of the periodontal ligament space results from tumor infiltration along this area, and is one of the earliest radiological signs.<sup>2-3,7</sup> However, this is not pathognomonic for osteosarcoma and may be seen with other neoplasms.<sup>3,13</sup> This neoplasm usually involves the roots of the teeth, with a narrowing of the root described as a "spiking" resorption. Radiographic evaluation is very important for diagnosis. In this case the widening of the periodontal ligament space observed in the periapical radiography played an important role, in conjunction with others features shown in the panoramic radiography.

Imaging studies in patients with osteosarcoma of the jaws should also include computed tomography (CT) scans of the head and neck which allow for

evaluation of cortical bone involvement and possible lymphadenopathy.<sup>2,3,7,13</sup> Nakayama et al.<sup>11</sup>, in a study of 10 osteosarcomas of the jaw, evaluated the association between CT findings, histological features, and the outcome of the tumor. These authors concluded that osteogenesis on the CT, tumor grade and the affected jaw site were considered to be prognostic factors. Some authors also point to the importance of magnetic resonance imaging in demonstrating the intramedullary and extraosseous components of osteosarcoma.<sup>2-3</sup> Unfortunately these are expensive exams for a Third World country and for those that depend on Public Health Service the wait is too long.

Osteosarcomas are subdivided in osteoblastic, chondroblastic and fibroblastic histological types, according to the extracellular matrix produced by tumor cells.<sup>7,11,13</sup> Histological type does not affect prognosis.<sup>13</sup> In this case, the tumor was classified as osteoblastic osteosarcoma due to the predominant osteoid matrix.

Surgical resection is the best treatment for osteosarcomas of the oral and maxillofacial region.<sup>2-3,6-7</sup> Wide resection with clear margins is very important for a favorable outcome.<sup>9,12</sup> Surgery can be supplemented with chemotherapy, radiation therapy or a combination of both, although the benefits for head and neck osteosarcoma are debatable.<sup>3,12</sup> According to Okinaka and Takahashi,<sup>6</sup> these adjuvant treatments are considered to be effective for preventing recurrence only when the primary lesion has been completely removed, although chemotherapy can be used for controlling occult distant metastasis.

Osteosarcomas of the jaws are less aggressive than those of the long bones, since they typically do not metastasize.<sup>1,2,4</sup> When metastasis occurs, it most often involves the lungs and brain, although regional lymph nodes may be involved.<sup>13</sup> The 5-year survival rate for primary osteosarcomas of the maxillary bones ranges from 30% to 40%.<sup>14</sup> This rate is up to 80% for those who underwent early surgical resection.<sup>13</sup> Local recurrence and intracranial invasion are the most common causes of death.<sup>3</sup>

For some authors<sup>15</sup> age was found to be an important factor in prognostic estimates. They believe that older patients have a better prognosis due to an increased resistance to the tumor. However, in a report of 32 cases of osteogenic sarcoma of the oral and maxillofacial region,

the 5-year survival rate was 100% in patients under the age of 19 years.<sup>9</sup> These authors believe that one of the reasons for high survival rate is that young patients respond better to radiation therapy or chemotherapy.

In spite of the favorable prognosis and rare rate of metastasis for maxillary osteosarcomas, in this case the tumor was very aggressive and despite early diagnosis and treatment, the patient died due to cerebral metastasis, one and a half years after surgical resection.

## References

1. Soares RC, Soares AF, Souza LB, Santos ALV, Pinto LP. Osteosarcoma of mandible initially resembling lesion of dental periapex: a case report. *Rev Bras Otorrinolaringol* 2005;71:242-5.
2. Fernandes R, Nikitakis NG, Pazoki A, Ord RA. Osteogenic sarcoma of the jaw: a 10-year experience. *J Oral Maxillofac Surg* 2007;65:1286-91.
3. Jansisyanont P, Pazoki A, Ord RA, Zak M. Recurrent mass in the anterior maxilla. *J Oral Maxillofac Surg* 2001;59:415-20.
4. Zorzan G, Tullio A, Bertolini F, Sesenna E. Osteosarcoma of the mandibular condyle: case report. *J Oral Maxillofac Surg* 2001; 59:574-7.
5. Ajagbe HA, Junaid TA, Daramola JO. Osteogenic sarcoma of the jaw in na African Community: report of twenty-one cases. *J Oral Maxillofac Surg* 1986;44:104-6.
6. Okinaka Y, Takahashi M. Osteosarcoma of the maxilla: report of a case and review of the literature concerning metastasis. *J Oral Maxillofac Surg* 1997;55:1177-81.
7. Shimamoto H, Ozono K, Nakamura T, Akiyama H, Gamoh S, Tamaki J, et al. Osteosarcoma in the maxilla: case report. *Oral Radiol* 2006;22:37-40.
8. Gadwal SR, Gannon FH, Fanburg-Smith JC, Becoskie EM, Thompson LDR. Primary osteosarcoma of the head and neck in pediatric patients. *Cancer* 2001;91:598-605.
9. Yamaguchi S, Nagasawa H, Suzuki T, Fujii E, Iwaki H, Takagi M, et al. Sarcoma of the oral and maxillofacial region: a review of 32 cases in 25 years. *Clin Oral Invest* 2004;8:52-5.
10. Oda D, Bavisotto LM, Schmidt RA, McNutt M, Bruckner JD, Conrad EU 3rd, et al. Head and neck osteosarcoma at the University of Washington. *Head Neck* 1997;19:513-23.
11. Nakayama E, Sagiura K, Kobayashi I, Oobu K, Ishihashi H, Kanda S. The association between the computed tomography findings, histologic features, and outcome of osteosarcoma of the jaw. *J Oral Maxillofac Surg* 2005;63:311-8.
12. Patel SG, Meyers P, Huvo AG, Wolden S, Singh B, Shaha AR, et al. Improved outcomes in patients with osteogenic sarcoma of the head and neck. *Cancer* 2002;95:1495-503.
13. Neville BW, Damm DD, Allen CM, Bouquot JE. *Patologia oral e maxillofacial*. 2nd ed. Rio de Janeiro: Guanabara Koogan; 2004.
14. Carnelio S, Pai K, Rao N, Salomon M, Ahasan A. A metastatic osteosarcoma to the maxilla: case report and review of the literature. *Quint Int* 2002;33:397-9.
15. Slootweg PJ, Muller H. Osteosarcoma of the jaw bones: analysis of 18 cases. *J Oral Maxillofac Surg* 1985;13:158-66.